

## A de novo reciprocal t(1;17) translocation with regular trisomy 21

---

Selda Simsek<sup>1</sup>, Aysegul Turkyilmaz<sup>1</sup>, Hilmi Isi<sup>1</sup>, Diclehan Oral<sup>1</sup>, Selahaddin Tekes<sup>1</sup>,  
Mehmet Nur Talay<sup>2</sup>

<sup>1</sup>Dicle University, Medical Faculty, Department of Medical Biology, Diyarbakir, Turkey

<sup>2</sup>Dicle University, Medical Faculty, Department of Pediatrics, Turkey

### Abstract

**Aim:** A -37 days male infant with Down syndrome exhibited an autosomal translocation t(1;17) in addition to trisomy 21.

**Case:** A 37 days male infant with Down syndrome was referred to Dicle University, Medical Faculty, Department of Medical Biology for karyotype analysis. On detailed clinical examination of the case was performed in the department of pediatry.

Cytogenetic analysis was performed by standart peripheral blood culture and GTG method by using phytohemagglutinin-stimulated lymphocyte. The chromosomal constitution of the patient was found to be 47, XX, t(1;17), +21. His parents showed a normal chromosome complement. The translocation must have been an apparently "balanced" one as the proband presented with typical features of Down syndrome alone.

**Conclusion:** Prenatal diagnosis should be offered even if there is no other important finding in the advanced maternal age, on prenatal consultation.

**Key Words:** Down syndrome, reciprocal translocation, interchromosomal effect

### Introduction

Translocations are chromosomal abnormalities that occure when chromosomes break and the fragments rejoin other chromosomes. When two nonhomologous chromosomes break and exchange fragments, new chromosomes, called derivative chromosomes, are formed. Reciprocal translocation is the most common type of translocation; it can further be classified into balanced and unbalanced rearrangements. There was no loss or increase of genetic materials in balanced translocations; however, unbalanced translocations showed the opposite result (1,2). It was suggested that translocations and other chromosomal rearrangements disturb meiotic disjunction mechanism and increase predisposition to trisomic offsprings. We report a case, who was born by IVF pregnancy technique, with regular Down syndrome and de novo reciprocal t(1;17) translocation carrier.

---

\* Corresponding author: E-mail: seldatsimsek@gmail.com  
Tel.: + 90. 412. 2488001/ (ext. 4835), Fax: + 90. 412. 2488440

## **Case Report**

A 37 days male infant with Down syndrome was referred to Dicle University Medical Faculty Department of Genetics for karyotype analysis. On detailed clinical examination of the baby was performed in the department of pediatrics. There was not any phenotypic finding except Down syndrome stigmata in the baby. A detailed interview was conducted with patient's mother and father before chromosome analysis. According to the analysis of pedigree observed that the couple was well-educated, there is no relationship between the mother and the father, the mother of patients was 38 years old and the father of patients was 44 years old, and the couple was married five years. As a result of detailed assessment proband's parents was sent to our laboratory because of unsuccessful IVF attempts and also father of proband was azospermia in 2010. We learned that chromosome analysis was done proband's parents and normal karyotype was detected.

The case (proband) was born as a result of IVF attempt of the couple's second pregnancy. There was no abnormal ultrasonographic indicator on on USG examination when proband's mothers during pregnancy. According to the information given by the family, Nuchal Translucency (NT) thickness in Combination with measurement of pregnancy-associated double test was made and calculated normal. Since there is no evidence of fetal anomaly and supports the direction of the baby, any invasive method did not suggest to the mother during pregnancy.

The karyotype of patient was performed in peripheral blood sample. The chromosomal constitution of the patient was found to be 47, XY, t(1;17).The figure 1 showed that the karyotype of the case. In spite of normal karyotype of chromosome analysis of the proband's parents; we made second time chromosome analysis and determined normal karyotype. We decided that the traslocation which detected the case was de novo.

We gave a genetic counseling to the family who has a child identified with down syndrom and the family still think to have another child. In the genetic counseling, we especially emphasized the importance of the prenatal diagnosis during the pregnancy earlier than fourth month.

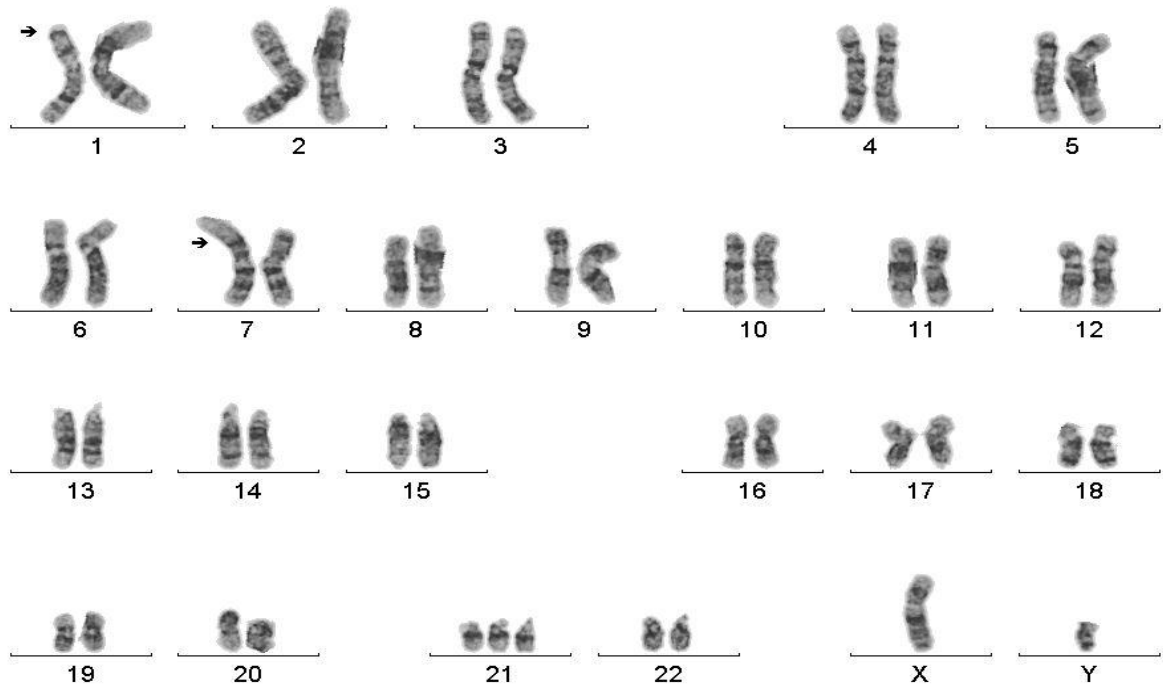


Figure 1. Karyotype of case.

## Methods

We obtained chromosome preparations from routine peripheral blood lymphocyte cultures. At least five GTG banded metaphases (minimal 500 band level) were evaluated for couple. Karyotypes were recorded according to the recommendations of the international standing committee on human cytogenetic nomenclature 1995.

Peripheral blood cultures were set up in F-10 nutrient media and with 20% fetal bovine serum. The cultures were stimulated with phytohaemagglutinin (PHA-M) and incubated for 72h at 37 °sub C. The cultures were arrested with colchicine (10 mg/ml) at 70,5th h and treated with 0.075 M KCl. The cultures were fixed with cornoy fixative (methanol: Acetic acid, 3:1). The chromosomes were prepared on prechilled slides and stored for three days at room temperature for ageing of the slides. The chromosome preparations were subjected to GTG-banding using standard procedure. Briefly, the slides treated with trypsin-EDTA in Sorensen's buffer for 30 seconds and stained with giemsa stain. At least 30 well-spread and banded metaphases were analyzed under microscope and karyotyped according to ISCN 2000.

## **Discussion**

Reciprocal translocations are usually harmless but they are associated with a high risk of unbalanced gametes and abnormal progeny. They come to attention either during prenatal diagnosis or when the parents of an abnormal child with an unbalanced translocation are karyotyped (1). When reciprocal translocation is detected in a patient on chromosome analysis, the parents of this patient should analysed for karyotype.

In this study we discussed a 37 days male infant with Down syndrome exhibited an autosomal translocation t(1;17) in addition to trisomy 21. Trisomy 21 and structural rearrangement has been reported as a very rare condition in the literature (3,4,5).

Cyrus et al reported that a 4-year-old girl with Down syndrome exhibited an autosomal translocation t(2;18) in addition to trisomy 21. Their case's parents showed a normal chromosome complement (5) as our case. But Hou and Wang presented a 3-month-old male infant with Down's syndrome resulting from de novo trisomy 21 had an additional reciprocal translocation between the long arms of chromosomes 4 and 9: 47,XY,+21,rcp t(4;9)(q35;q22.3) Both C- and Ag-NOR bandings showed that the extra chromosome 21 was maternal in origin, but that the translocated chromosome 9 was from the father in their study (6).

Delgado et al reported the case of a family with a t(1;15) in three generations which was identified through the evaluation of a patient with classical trisomy 21 (3).

Tunca et al. Presented that an autosomal translocation carrier fetus with trisomy 21: 47,XX,+21, t(3;8)(p21;q24) in prenatal diagnosis (4).

The present case stressed that the importance of prenatal diagnosis in the advanced maternal age (there is no other important findings such as abnormal biochemical markers in the maternal serum or sonographically detectable markers on USG examination)

## **References**

1. Nussbaum RL (2001). Thompson and Thompson Genetics in Medicine. Six ed., WB.Saunders Company,172-175.
2. Chang YW, Wang PH, Li WH, Chen LC, Chang CM, Sung PL, Yang MJ, Cheng LY, Lai YL, Cheng YY, Yeh CC, Chang WH, Wang SY, Chen SR, Yen MS, Chao KC (2013). Balanced and unbalanced reciprocal translocation: An overview of a 30-year experience in a single tertiary medical center in Taiwan. *Journal of the Chinese Medical Association*, 76: 153-157
3. García-Delgado C, Bahena-Martínez E, Aparicio-Onofre AGuevara-Yañez R,Cervantes-Peredo A, Azotla-Vilchis OC, Estrada-Mena J, Luna-Angulo A, Villa-Morales J, Moran-Barroso VF (2010). A familial reciprocal translocation t(1;15) in three generations identified in a regular trisomy 21 patient. *Genet Couns*, 21(3): 299-306.
4. Tunca Y, Deveci MS, Koc A, Kaya H, Alanbay I, Coksuer H, Dede M (2013). Prenatal diagnosis of an autosomal translocation with regular trisomy 21. *Fetal Pediatr Pathol*. Jun; 32(3):210-212
5. Cyrus C, Kaur H, Koshy T, Thankanadar J, Nallathambi C (2007). A de novo reciprocal t(2;18) translocation with regular trisomy 21. *Genet Test*,11(4): 459-462.
6. Hou JW and Wang TR (1994). Cytogenetic investigations in trisomy 21 with reciprocal 4/9 translocation: report of a case. *J Formos Med Assoc*, 93(11-12): 958-960